



12ª Conferência Mundial de Saúde Rural da WONCA

IV Congresso Sul-Brasileiro de
Medicina de Família e Comunidade

Saúde Rural: uma necessidade emergente

3 a 5 de abril de 2014 | 2 de abril: Atividades Pré-evento
6 e 7 de abril: Atividades Pós-evento

Serrano Resort Convenções & SPA | Gramado | RS | Brasil





Procedimentos Frequentes em APS

Roberto Umpierre

Médico de Família e Comunidade

Professor da FAMED/UFRGS




Procedimentos em APS

- **Acesso**
- **Integralidade**
- Longitudinalidade
- Coordenação do Cuidado

Procedimentos Frequentes em APS

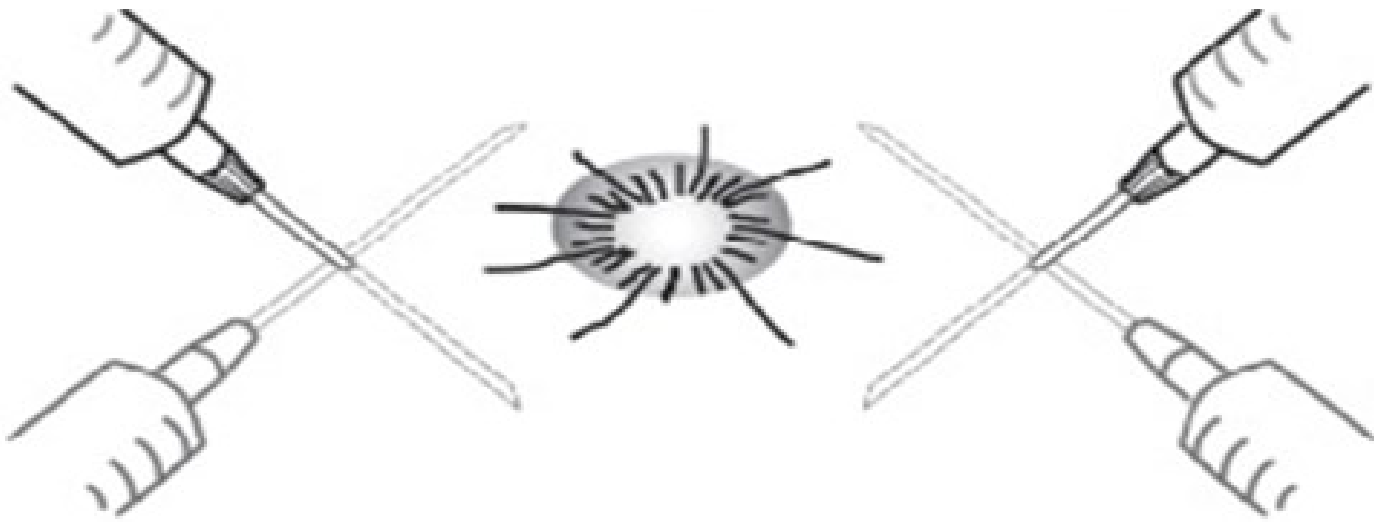- Drenagem de Abcesso
- Cantoplastia
- Drenagem de Hematoma Sub-ungueal
- Retirada de Anel
- Inserção de DIU
- Lavagem Otológica
- Corpo Estranho em Orelha Externa
- Zíper Preso
- Remoção de Anzol
- Tamponamento Nasal Anterior



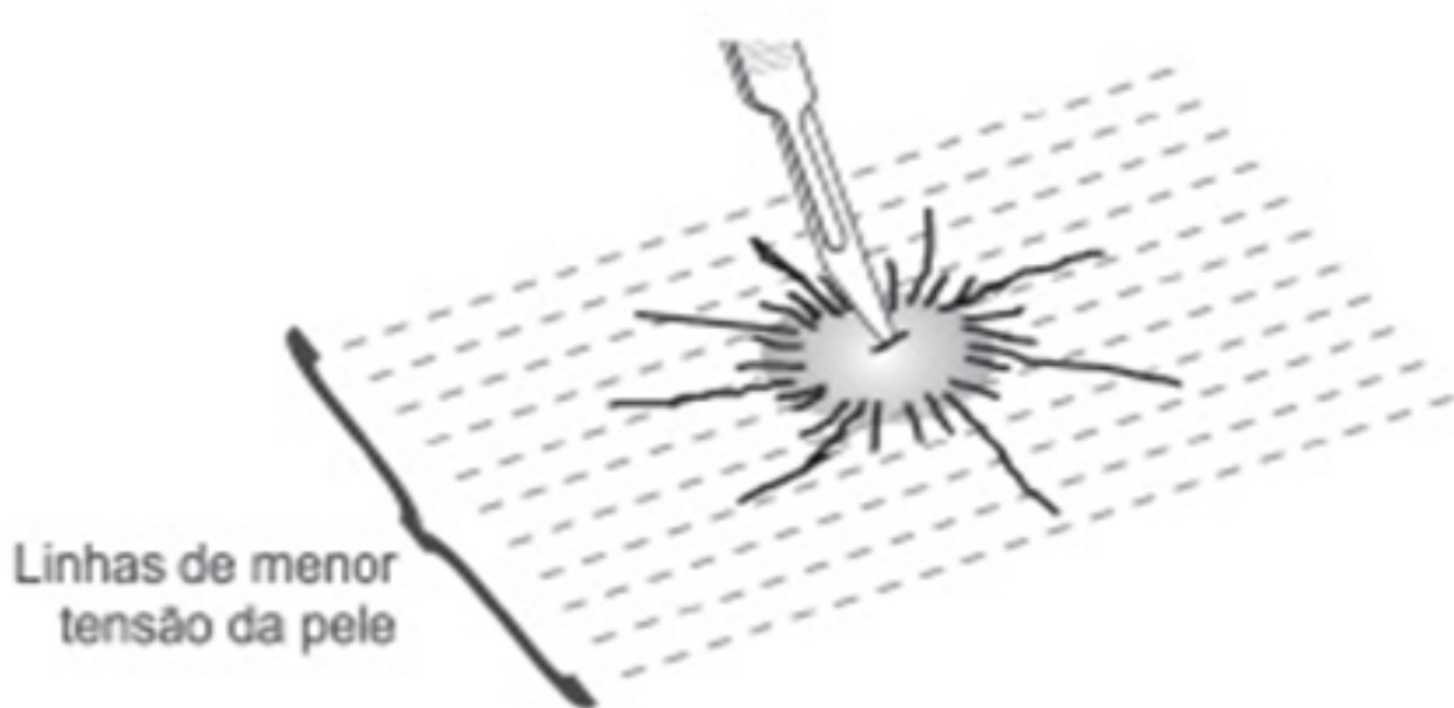
Drenagem de Abcesso

- Antissepsia
- ANESTESIA
- Incisão
- Drenagem

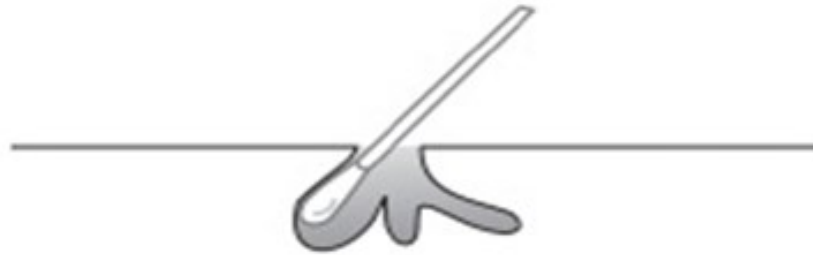Drenagem de Abcesso



Drenagem de Abcesso

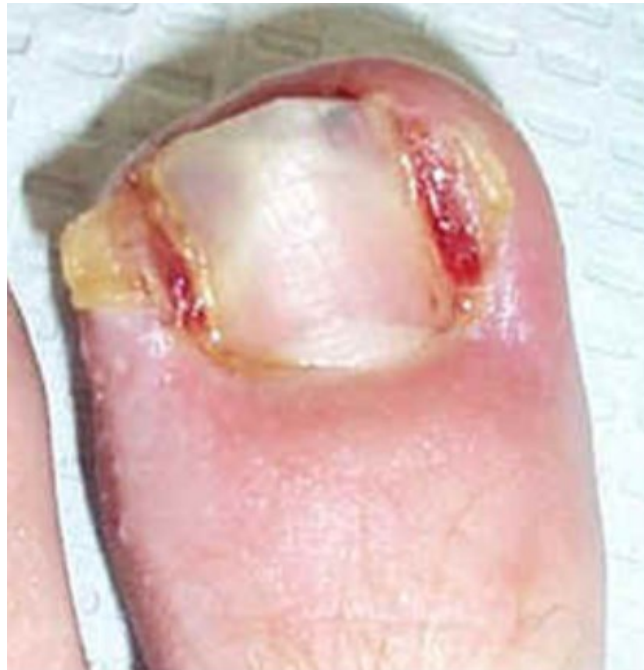

Drenagem de Abcesso





Cantoplastia





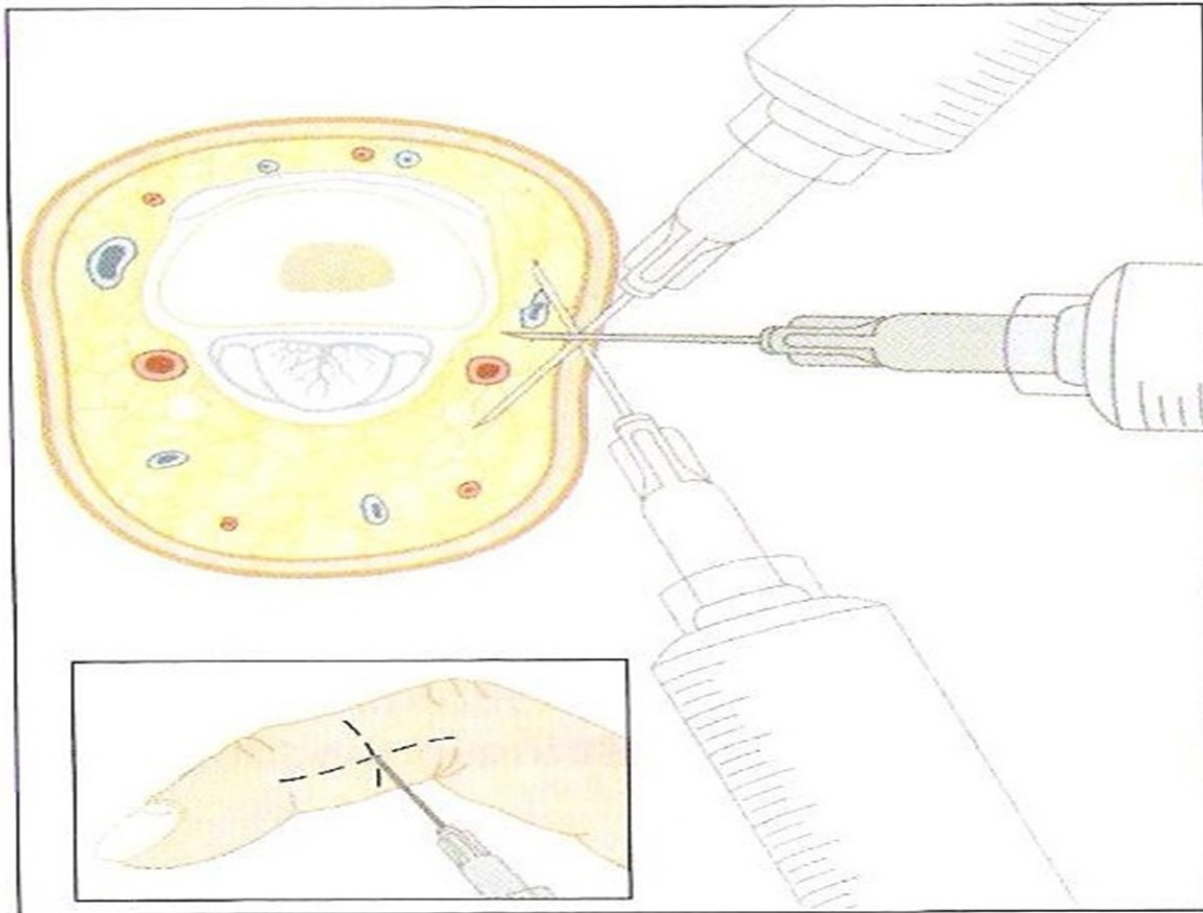
Cantoplastia

- Antissepsia
- Anestesia – Bloqueio Digital
- Remoção do Granuloma
- Avulsão e Remoção do canto ungueal
- Curetagem do Leito Ungueal



Cantoplastia

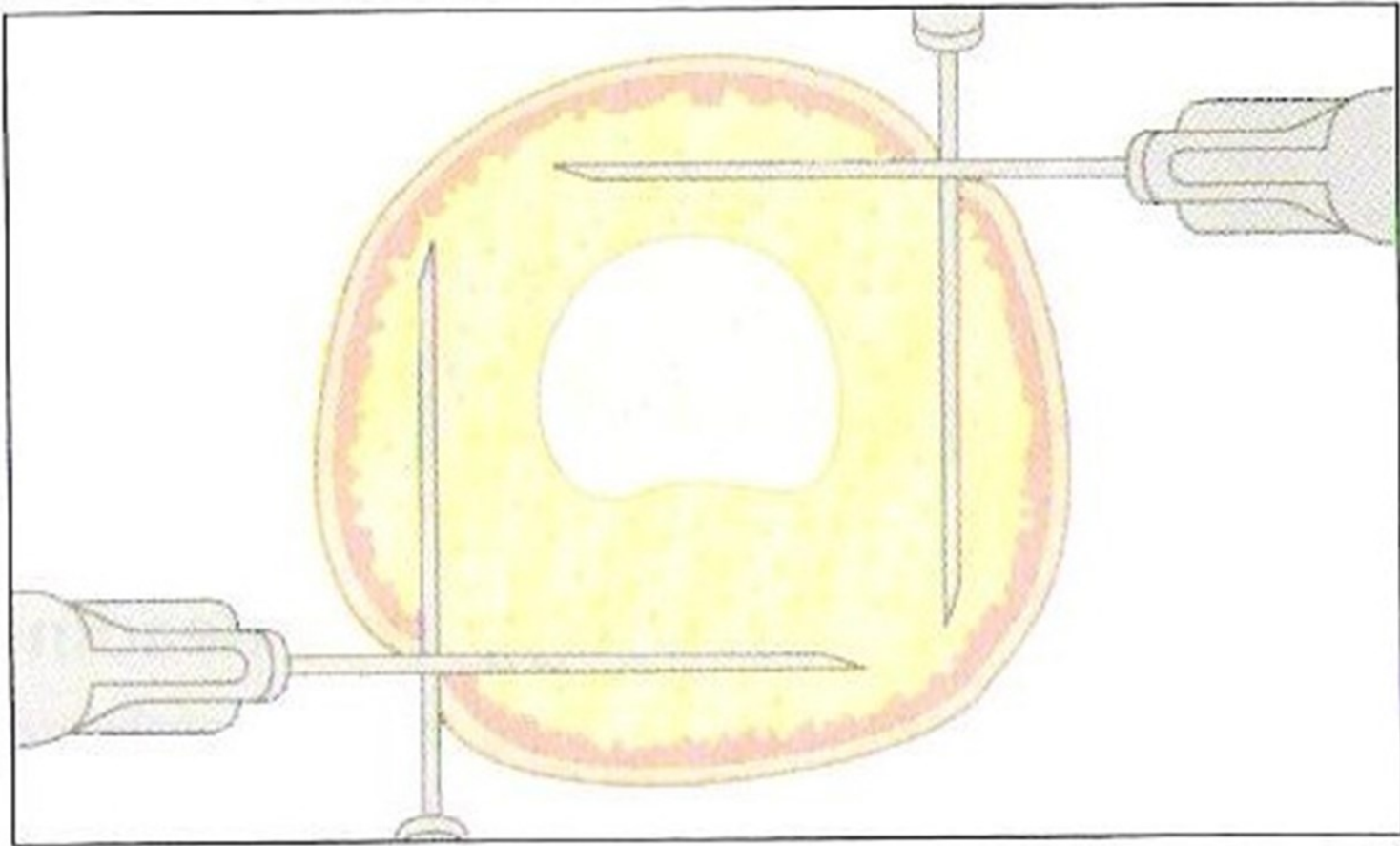
➤ Bloqueio Digital





Cantoplastia

➤ Bloqueio Digital





Cantoplastia

➤ Bloqueio Digital

- Observação:

- ✓ NUNCA usar anestésico com vasoconstritor em extremidades do corpo

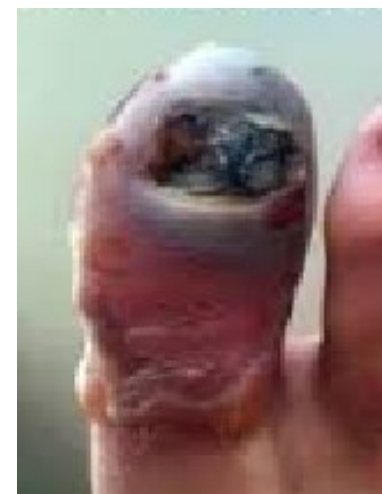

Cantoplastia

➤ Bloqueio Digital

- Observação:

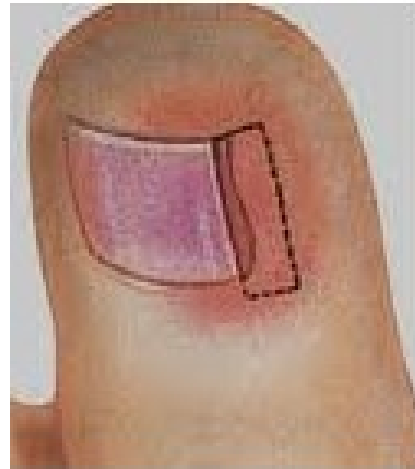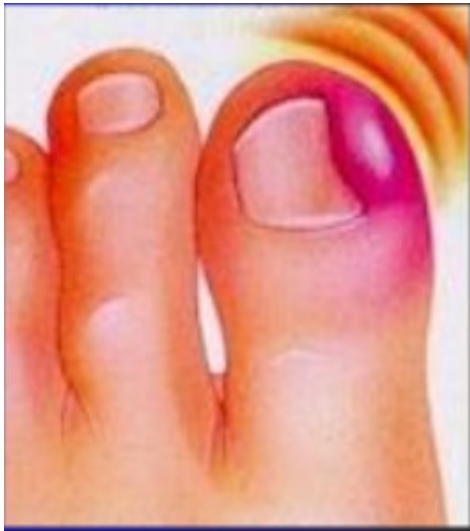
✓ NUNCA usar anestésico com vasoconstritor em extremidades do corpo





Cantoplastia

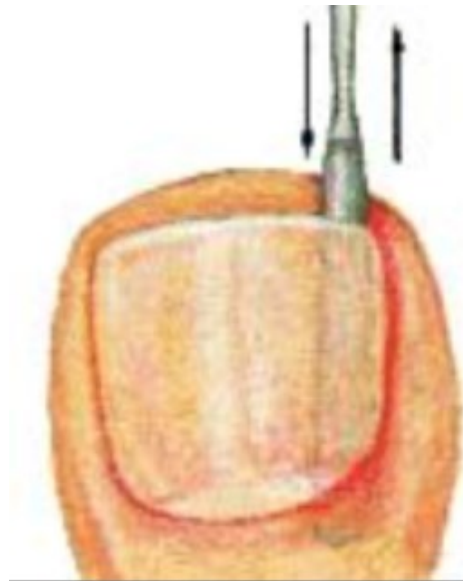➤ Remoção do Granuloma





Cantoplastia

➤ Avulsão do Canto Ungueal





Cantoplastia

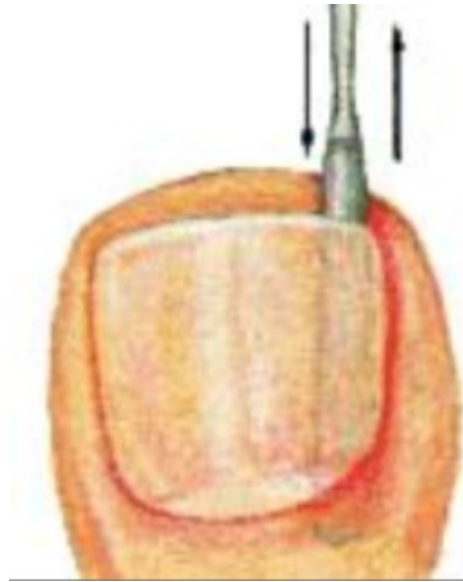➤ Avulsão do Canto Ungueal





Cantoplastia

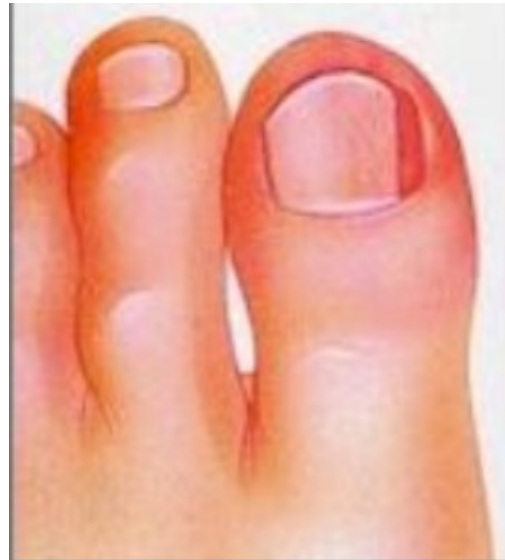
➤ Avulsão do Canto Ungueal





Cantoplastia

➤ Aspecto Final



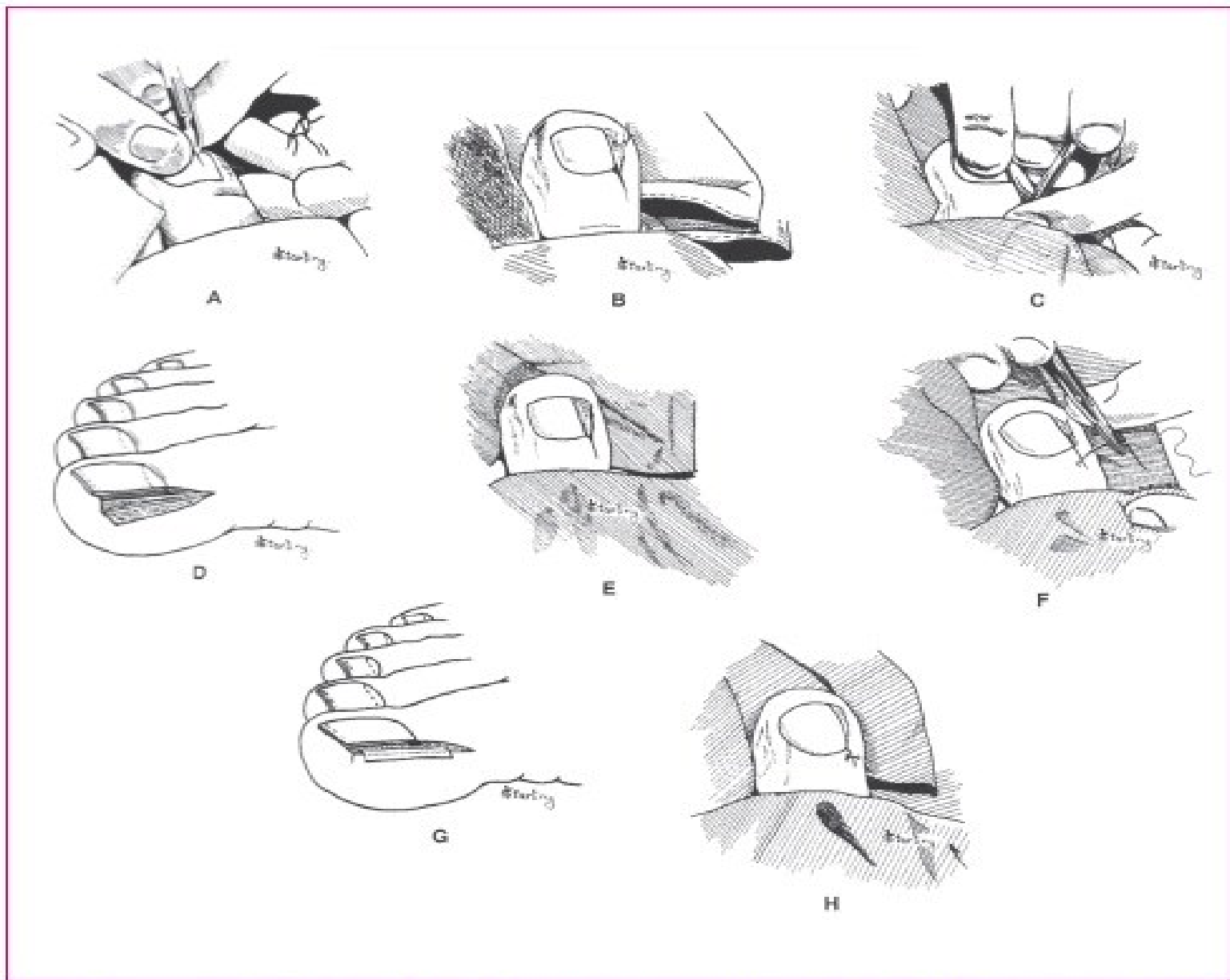
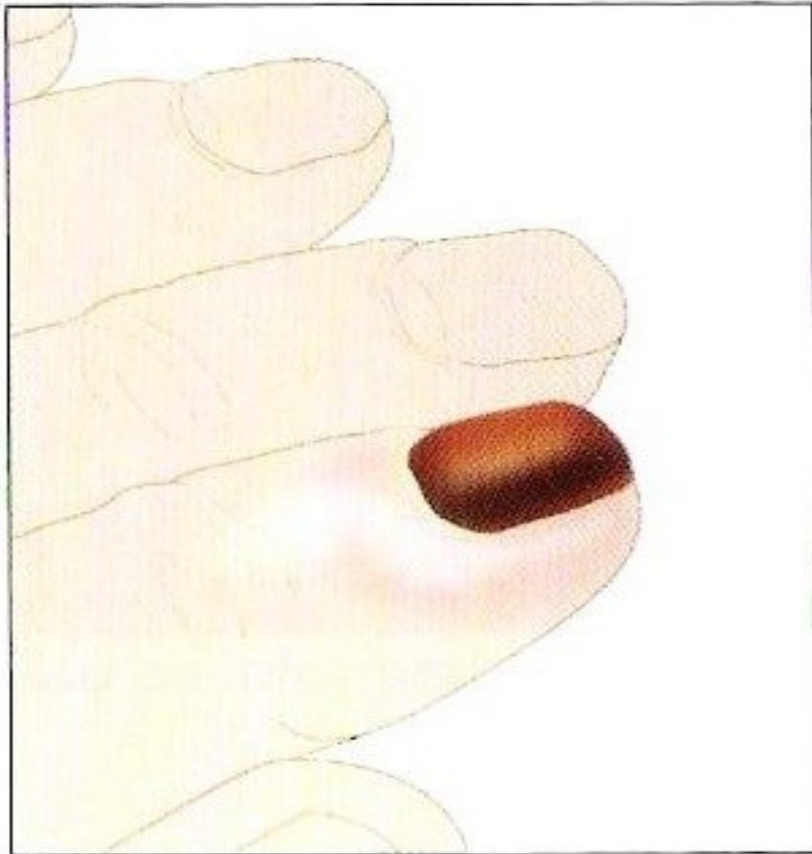
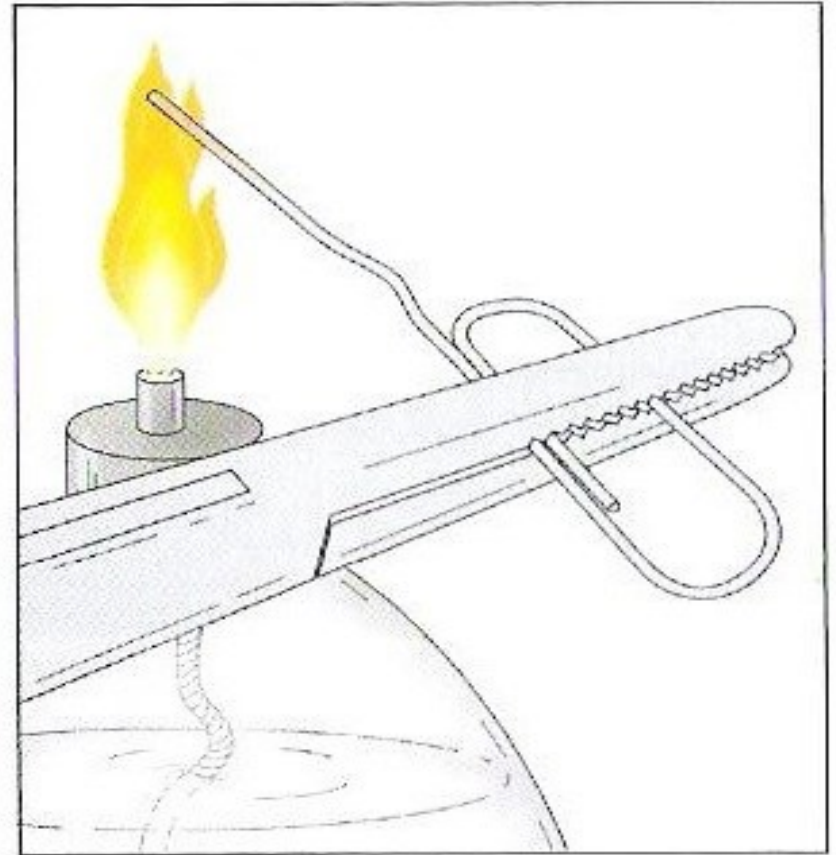


Figura 4 – Remoção em cunha da borda e matriz ungueais: A) incisão em cunha no sentido distal para proximal; B) incisão prolonga-se até a base da unha; C) ressecção em cunha da borda ungueal e do tecido de granulação; D) detalhe da área ressecada; E) aspecto após curetagem do leito e matriz ungueais; F e G) aproximação das bordas da ferida com pontos simples ou com esparadrapo; H) resultado final.

Hematoma sub-ungueal

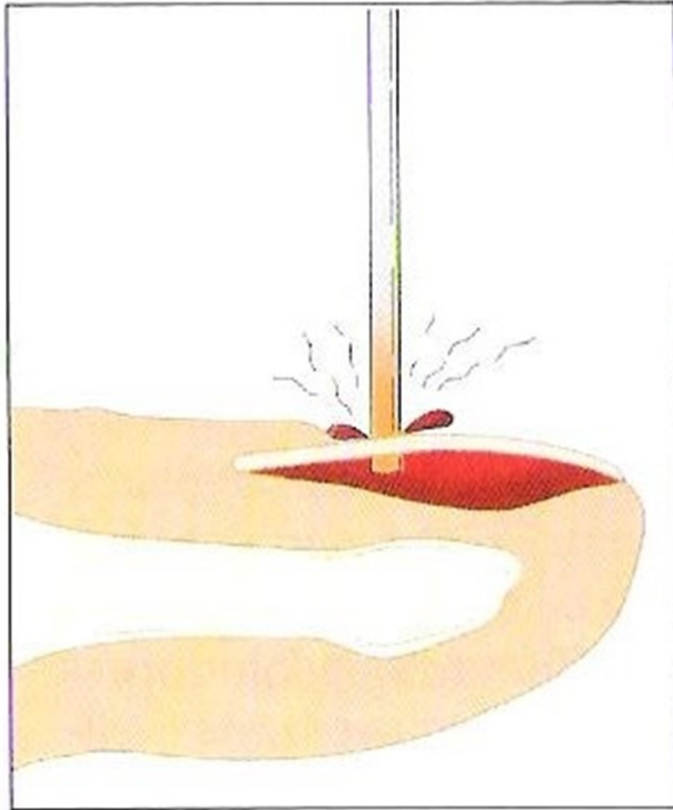


A

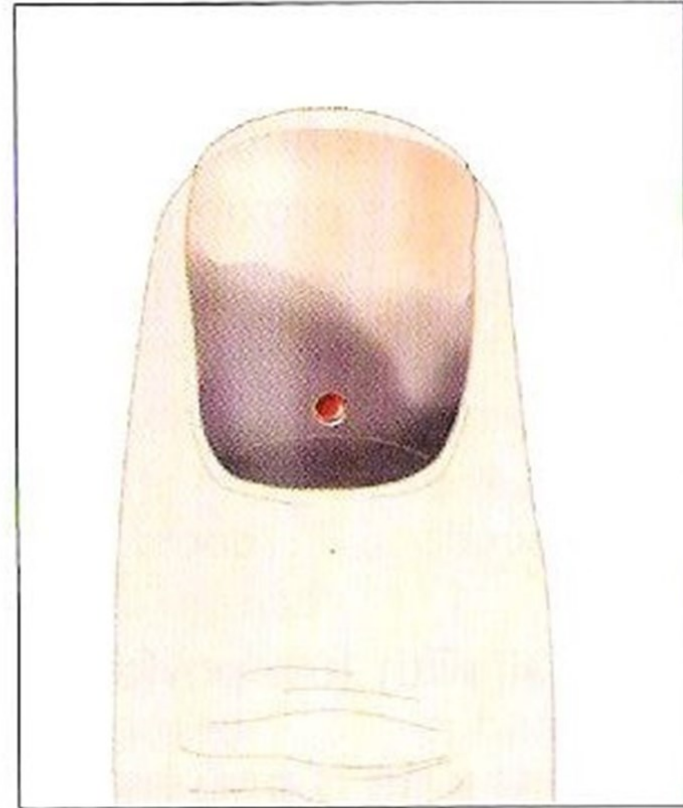


B

Hematoma sub-ungueal



C



D

Hematoma sub-ungueal

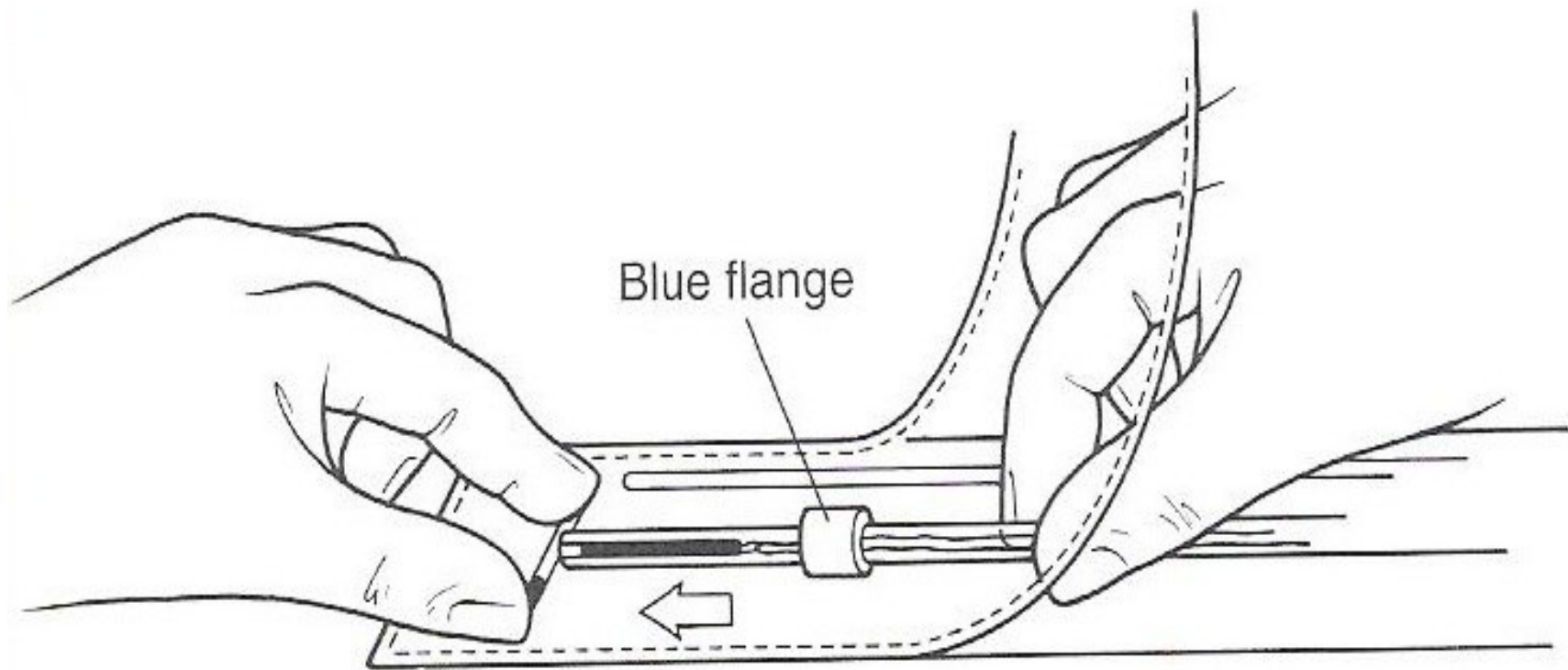
- Observação:
 - ✓ Não usar agulha

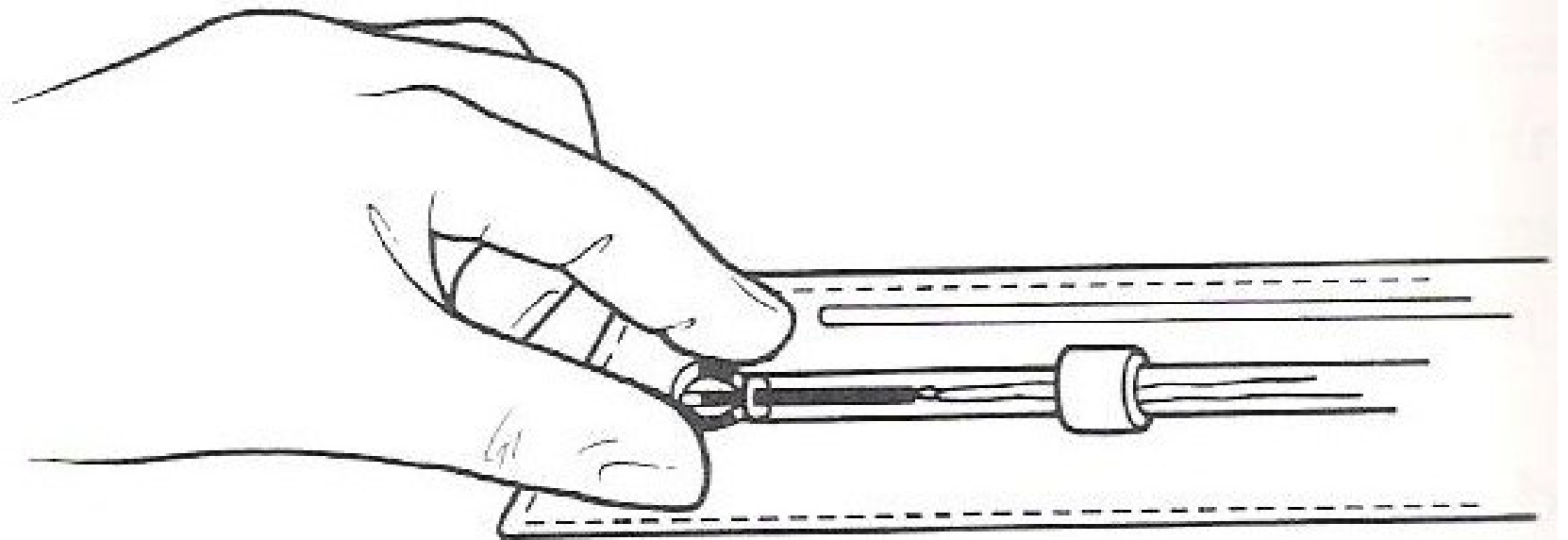
Inserção de DIU

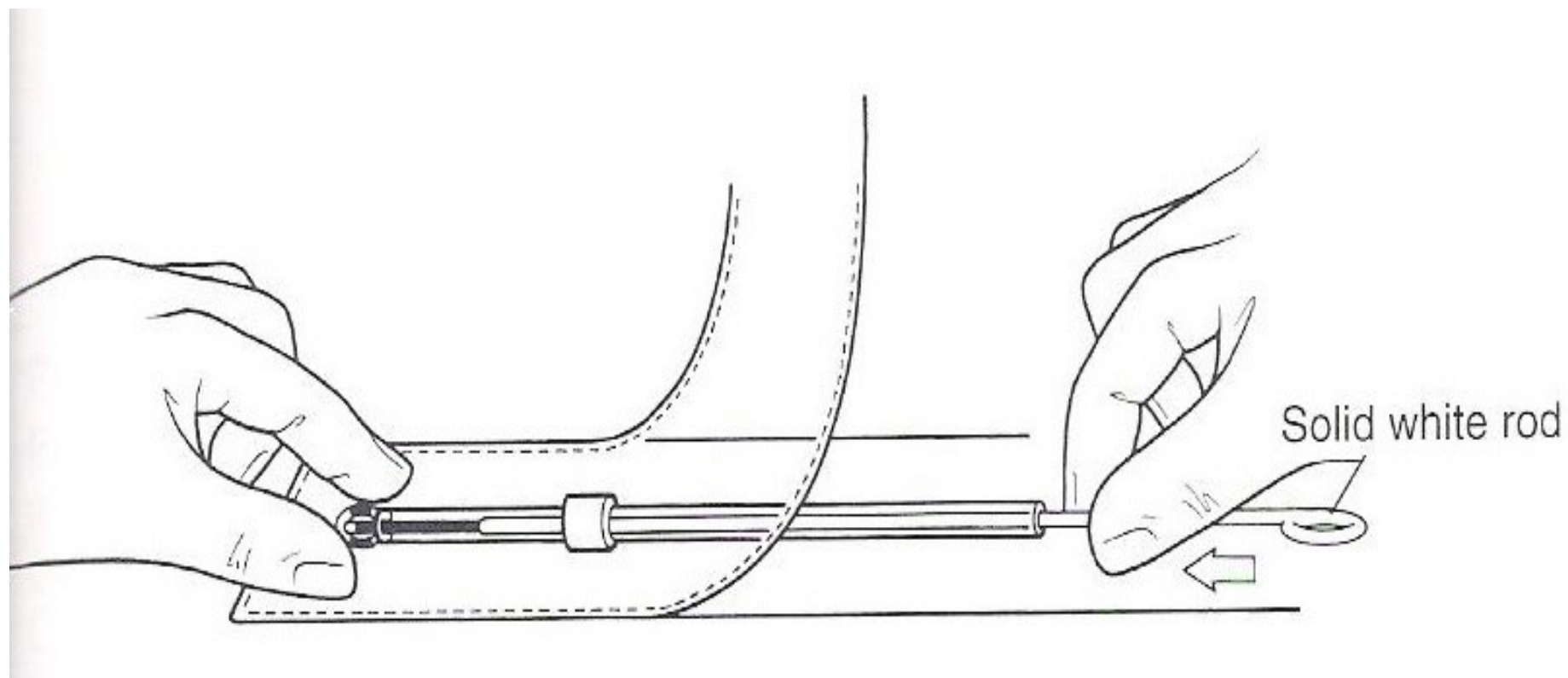
- Esclarecimentos sobre anticoncepção
- CP normal de no máximo 6 meses
- Exame ginecológico (toque e especular)
- Antissepsia
- Pinçamento da borda anterior do colo
- Histerometria
- Inserção do DIU

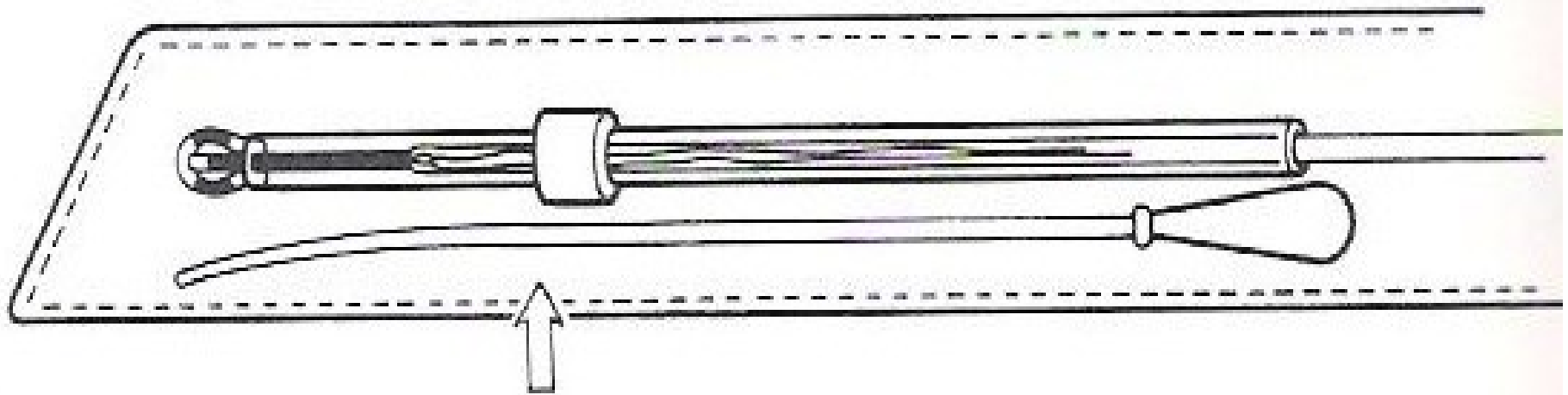
Inserção de DIU

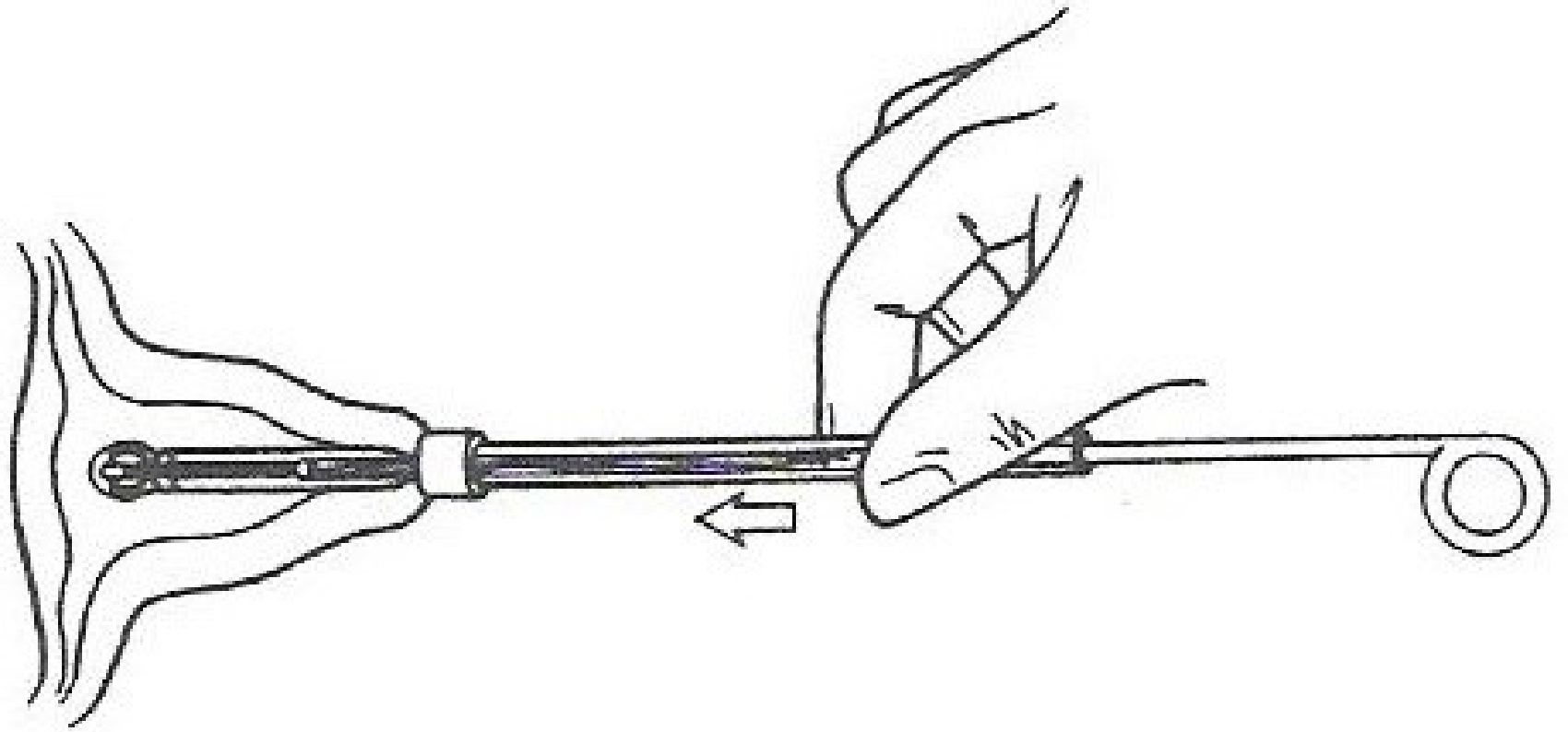
- VÍDEO

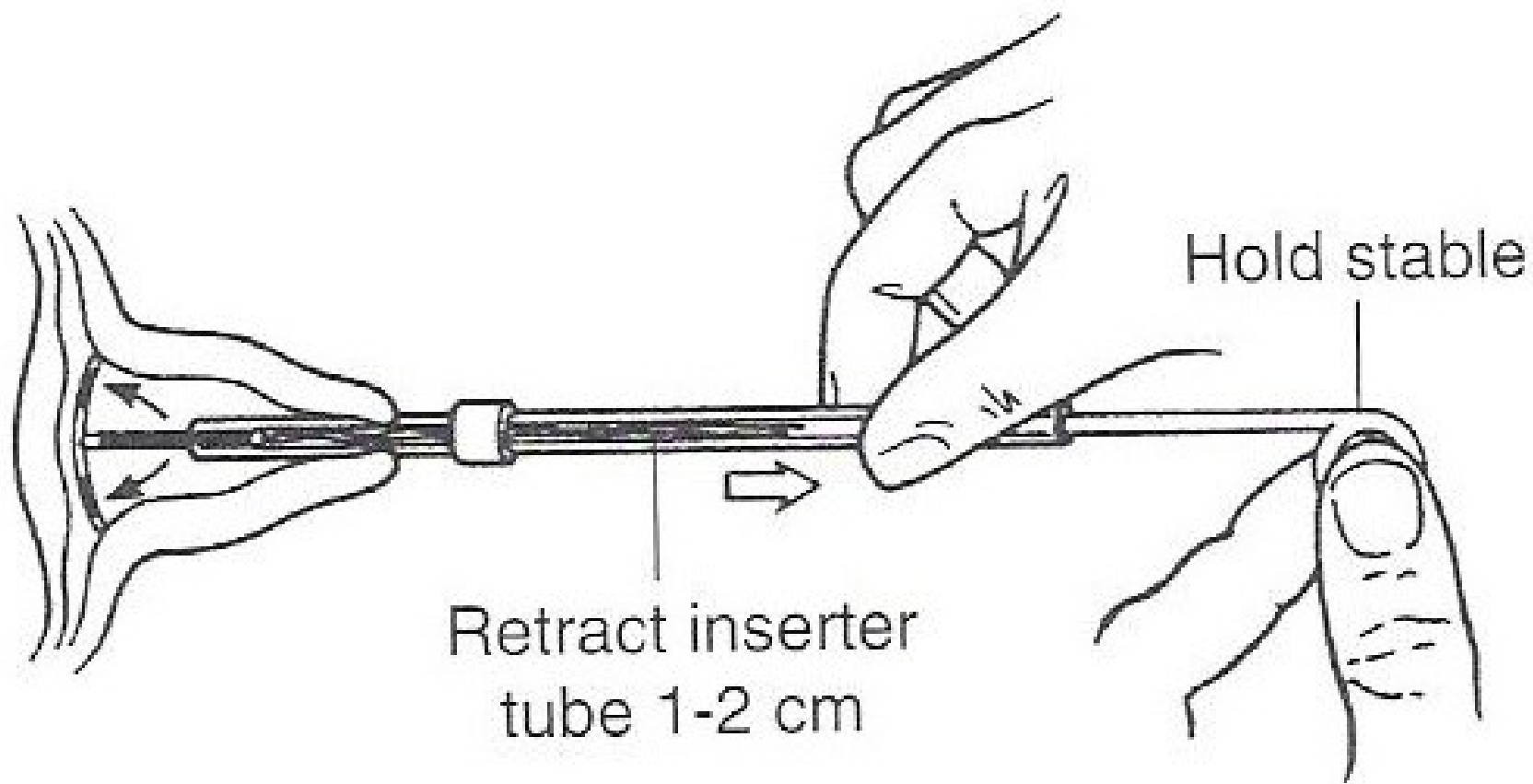


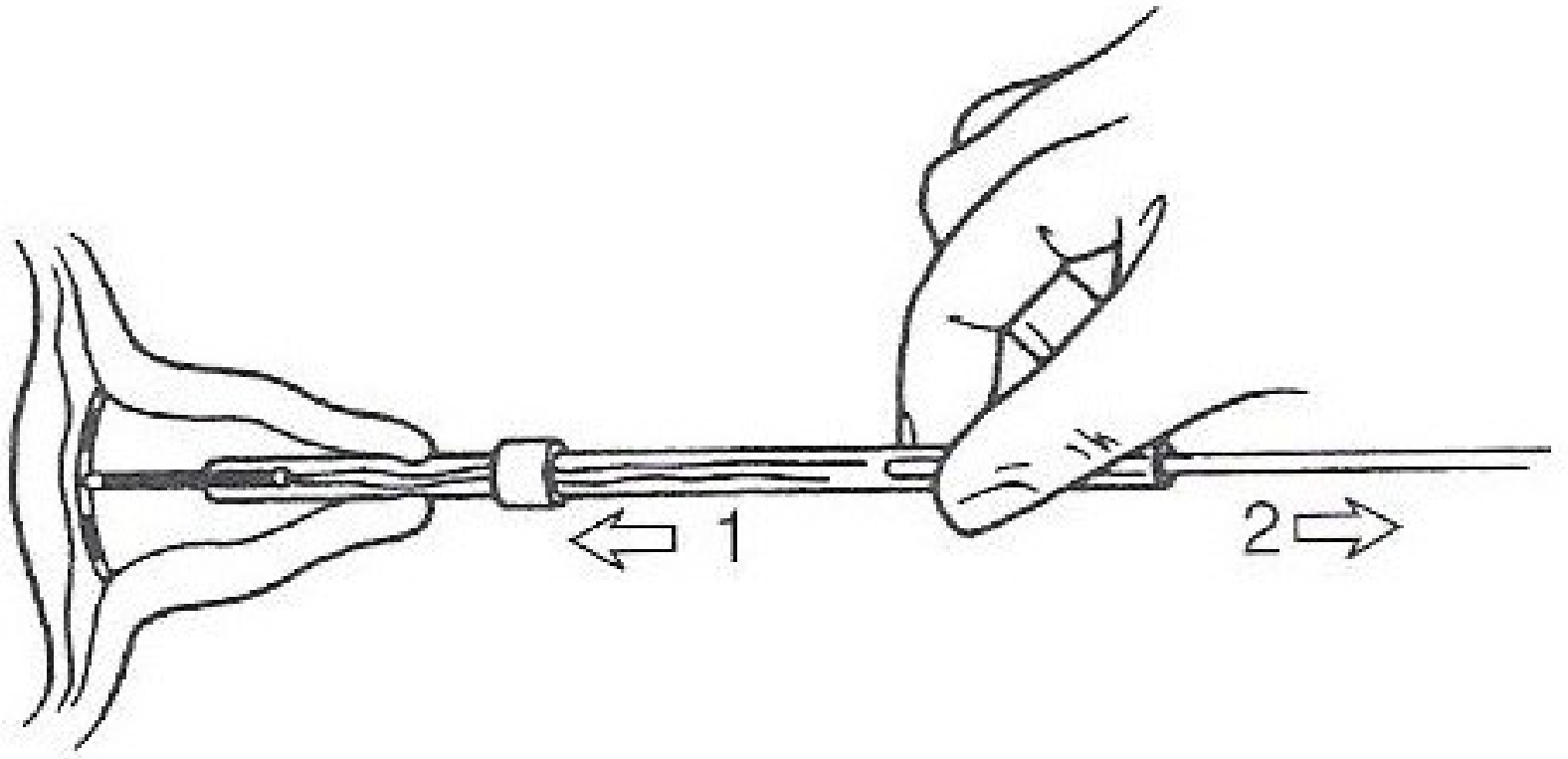


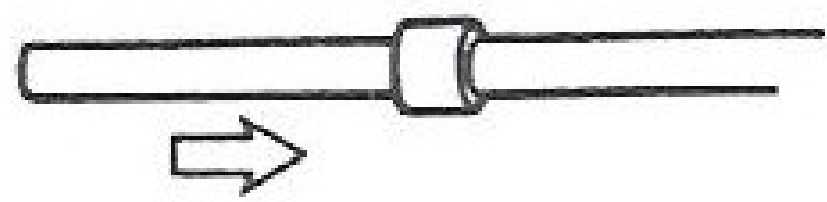
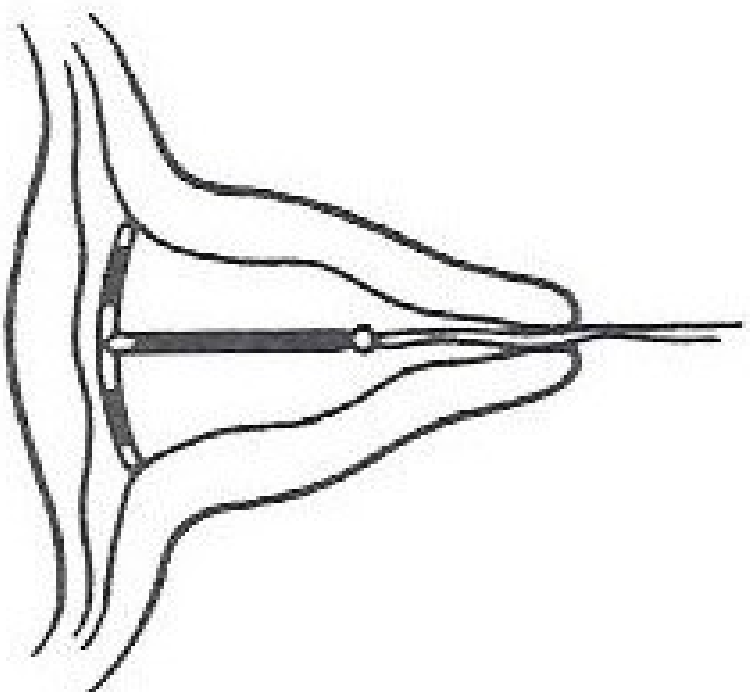


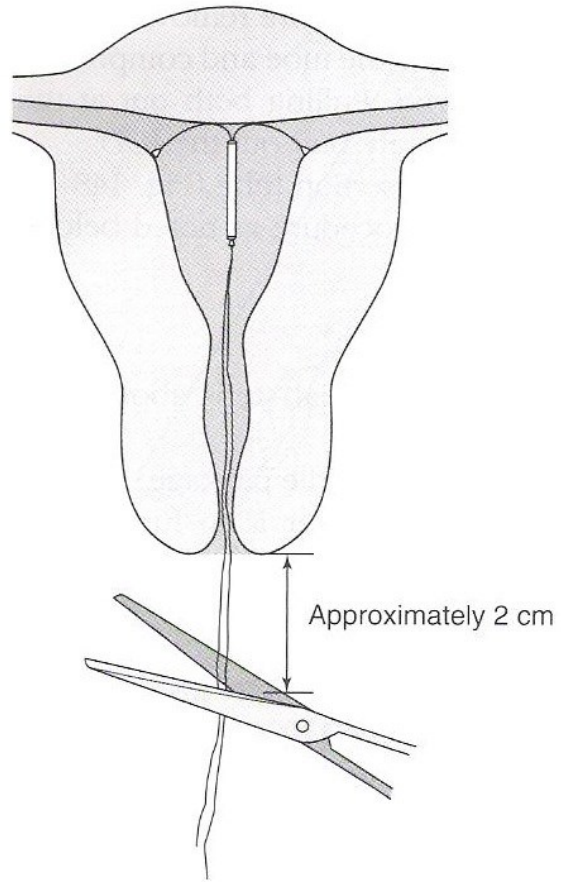






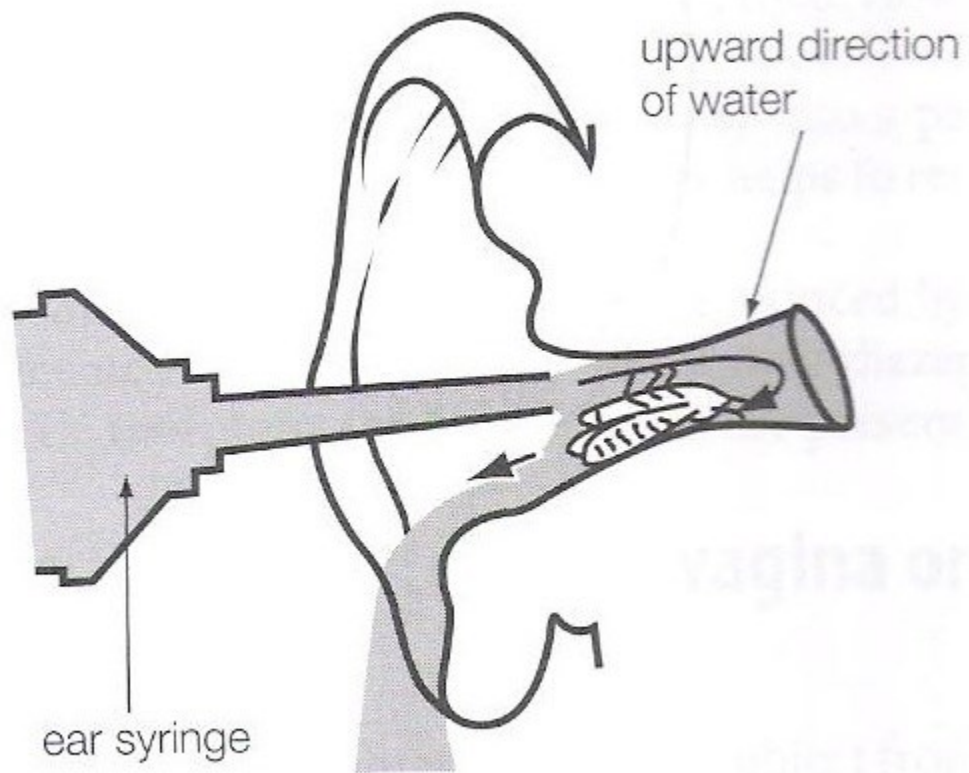






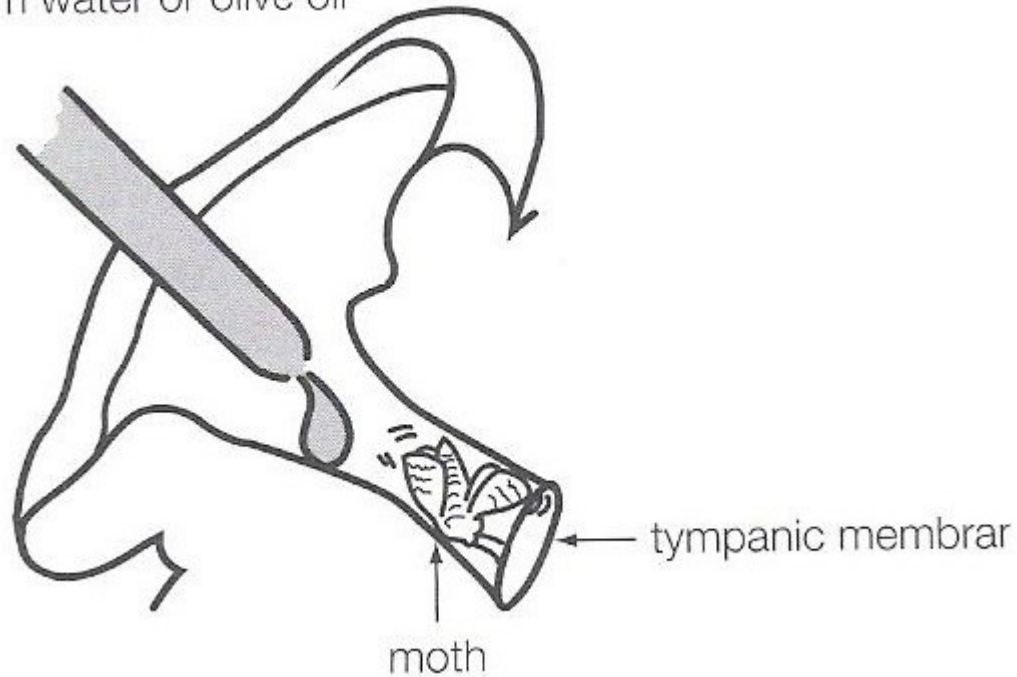
Lavagem Otológica

- Tampão de Cerumem
- Sem história de perfuração timpânica
- Ceruminolíticos
- Soro aquecido na temperatura do corpo

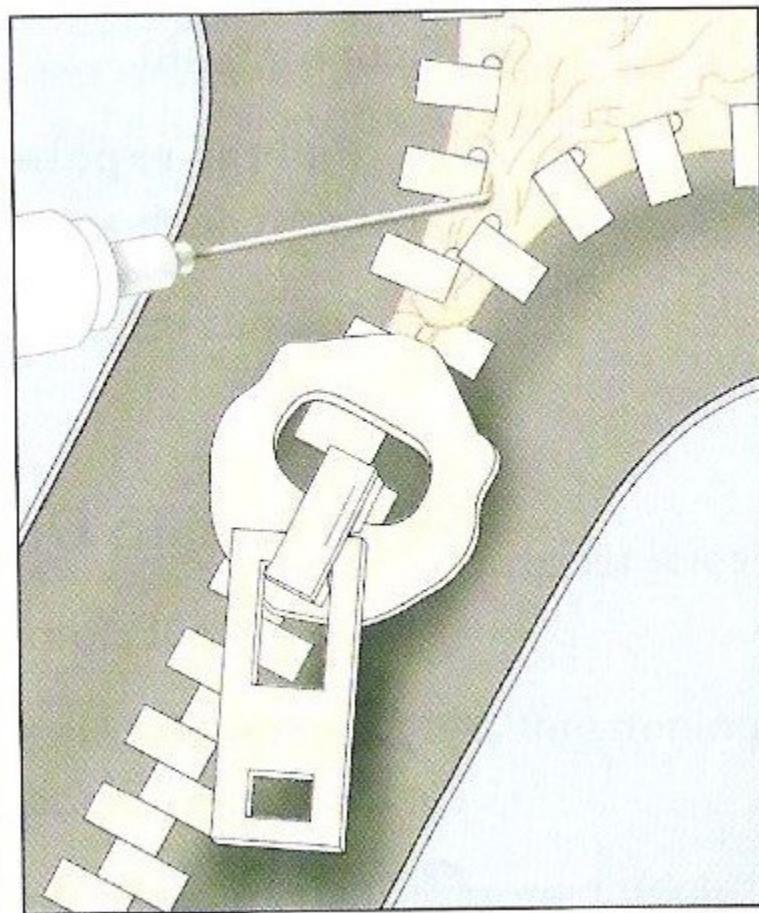
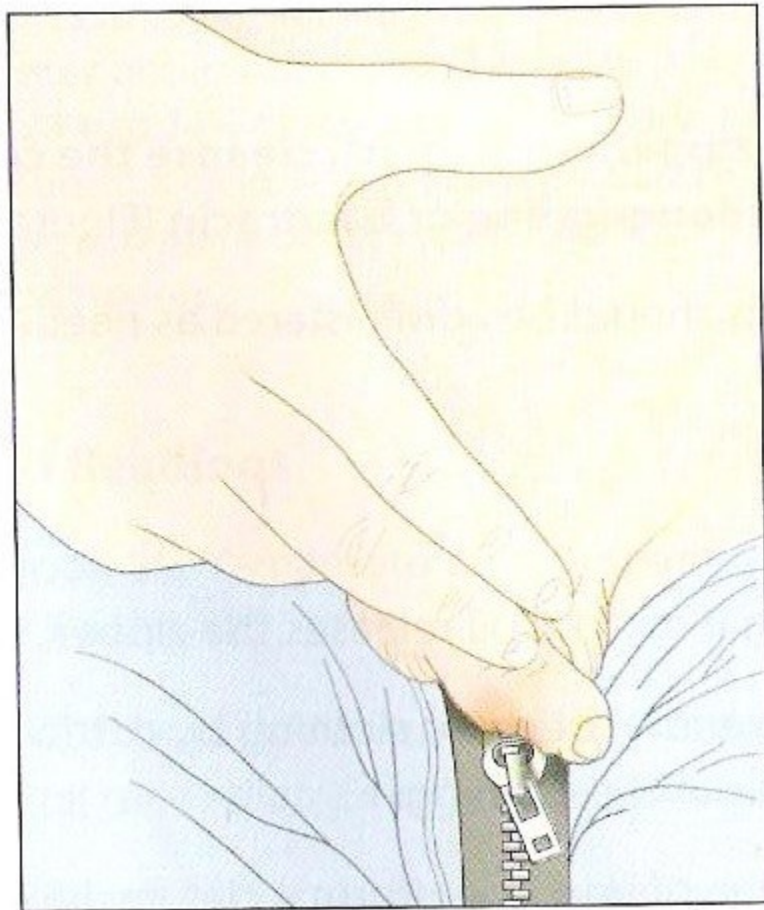


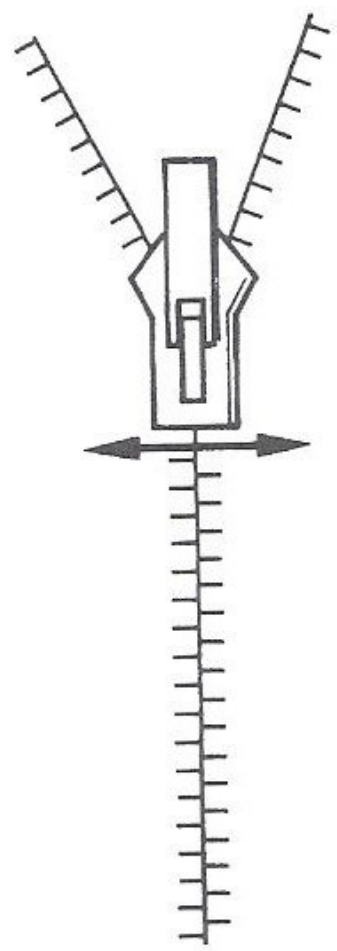
Corpo Estranho na Orelha

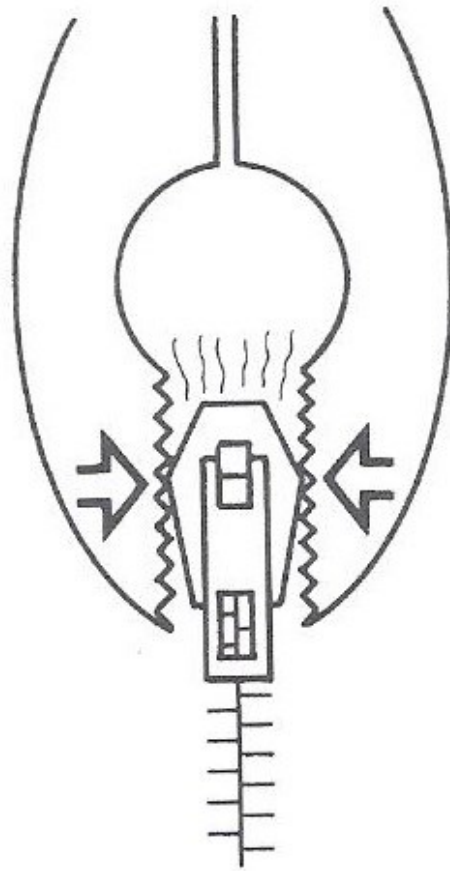
warm water or olive oil



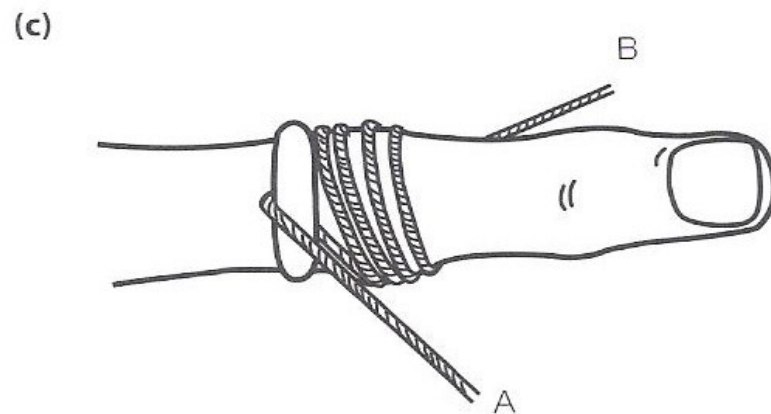
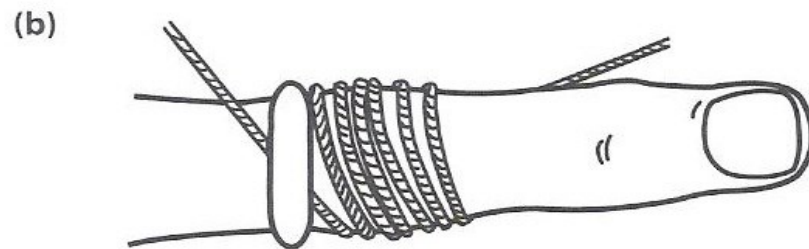
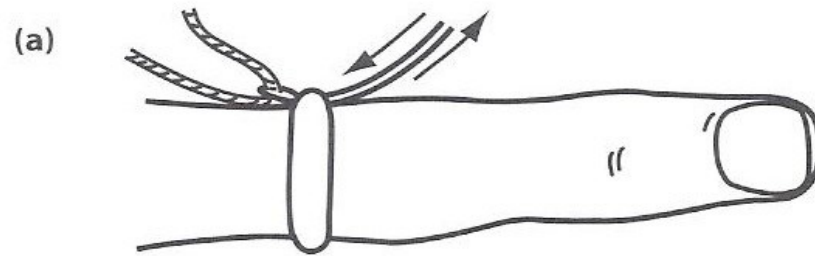
Zíper Preso



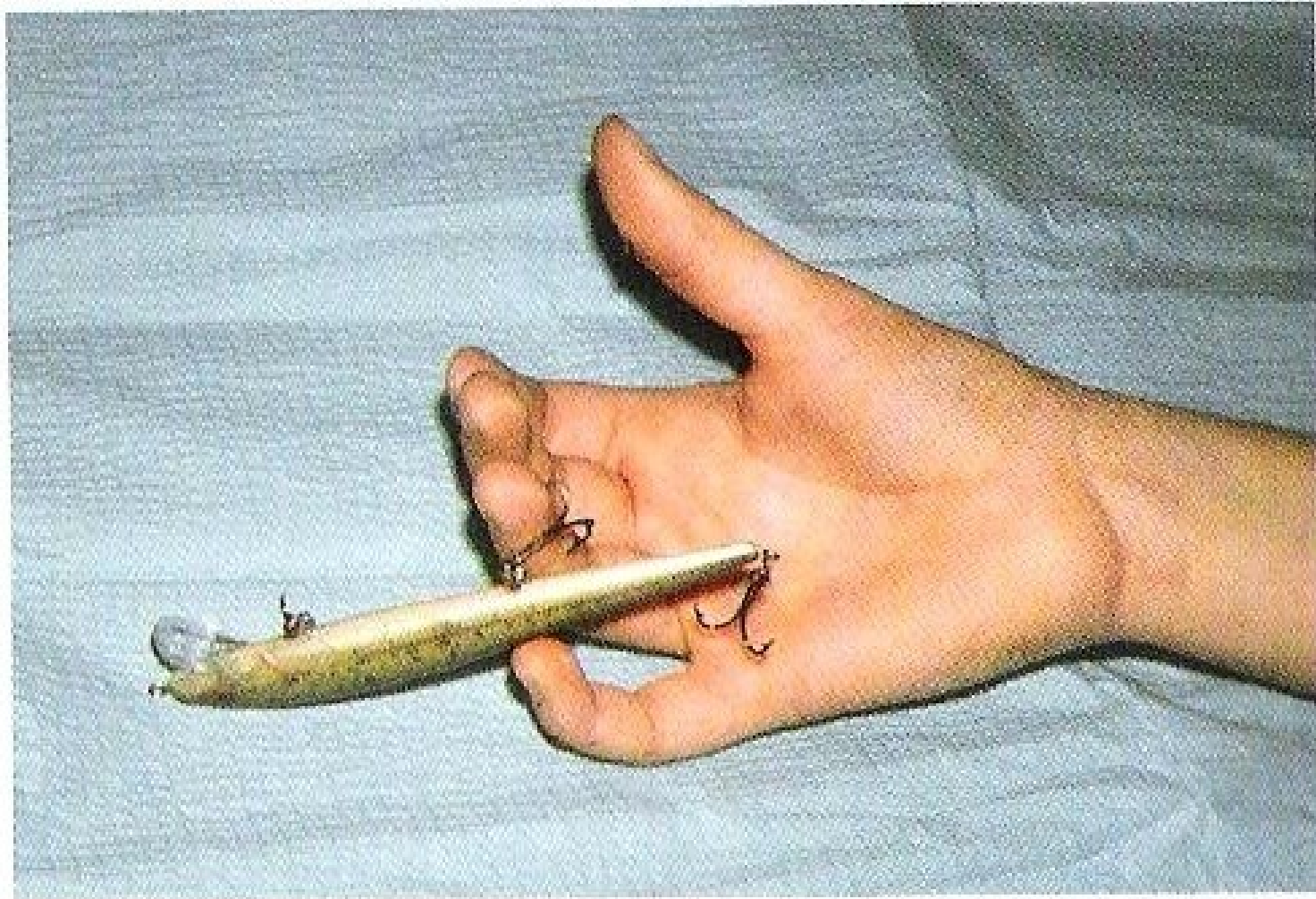

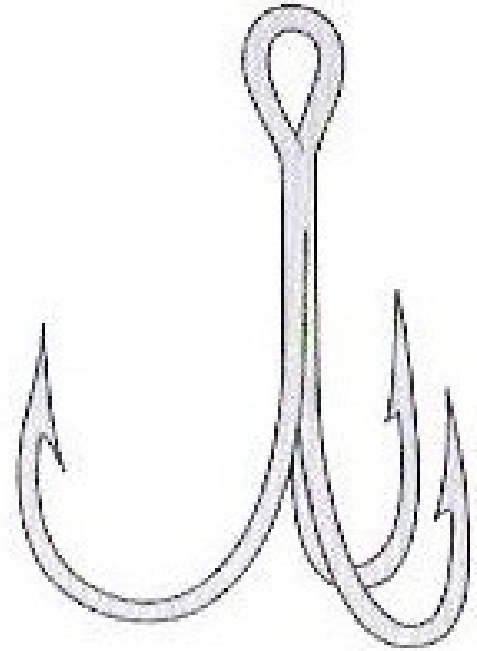
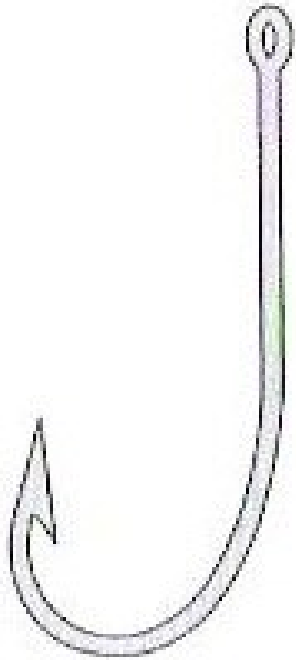


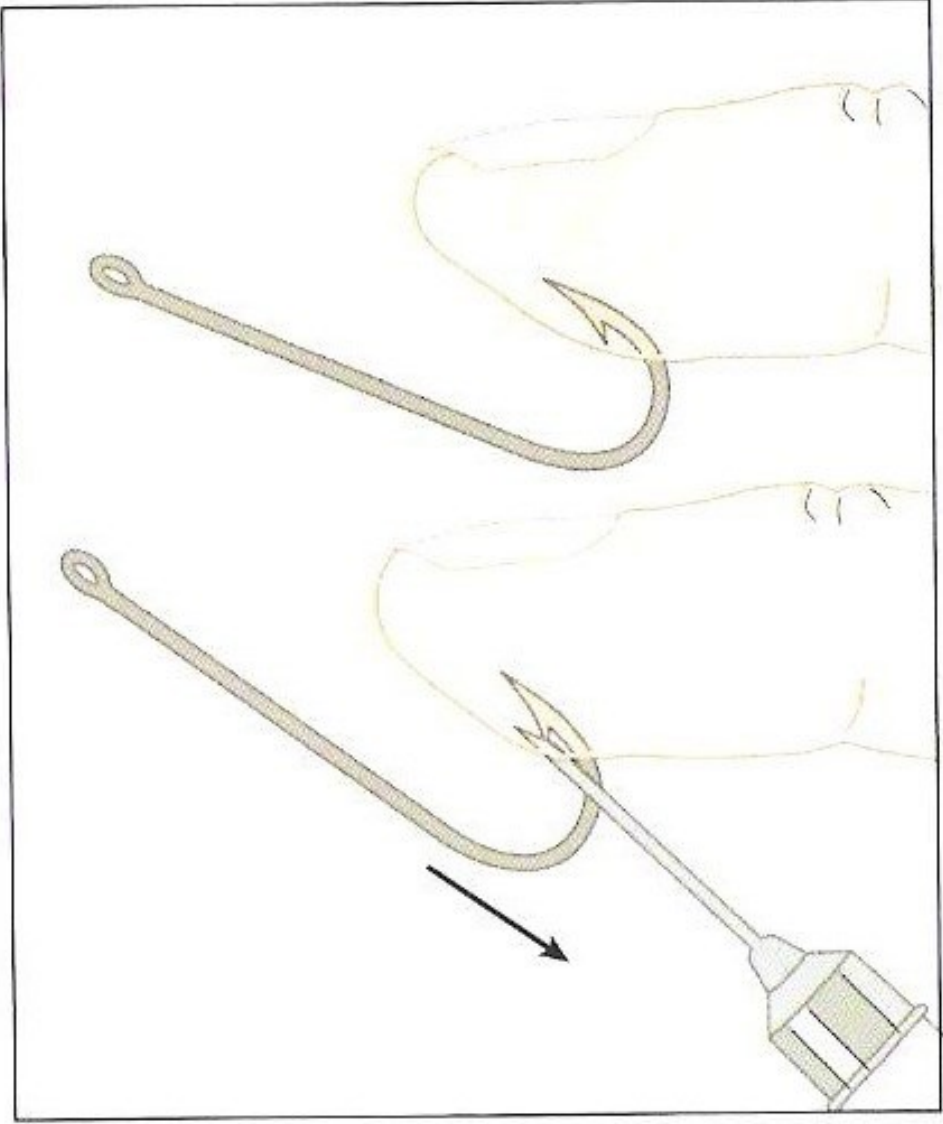
Retirada de Anel




Remoção de Anzol

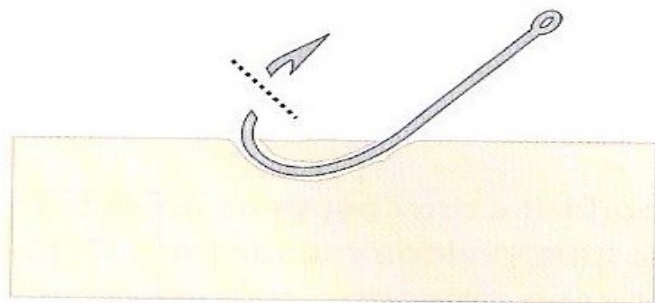




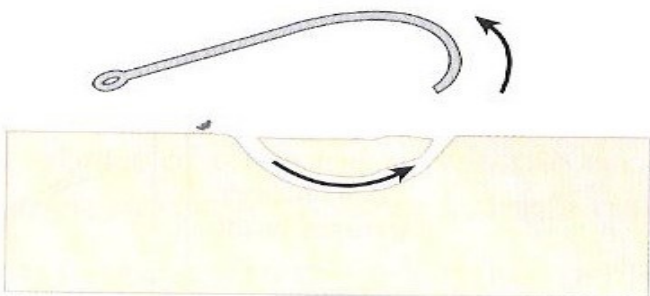




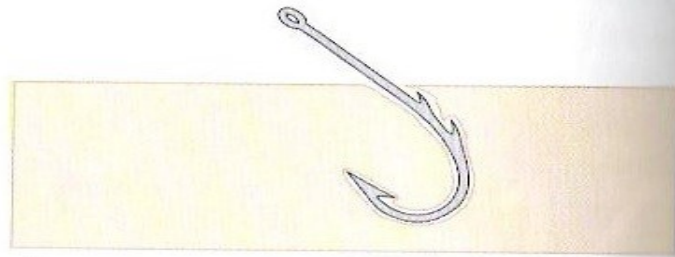
A




B



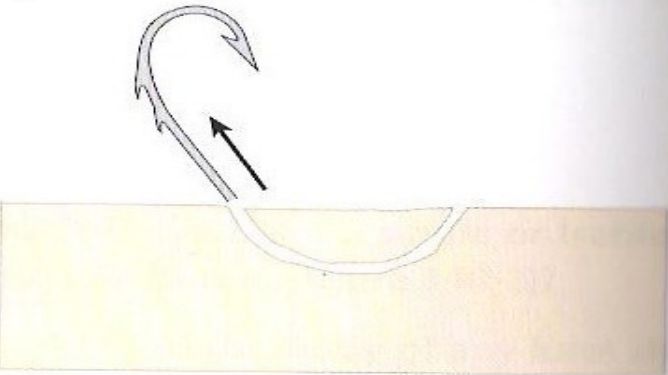
C



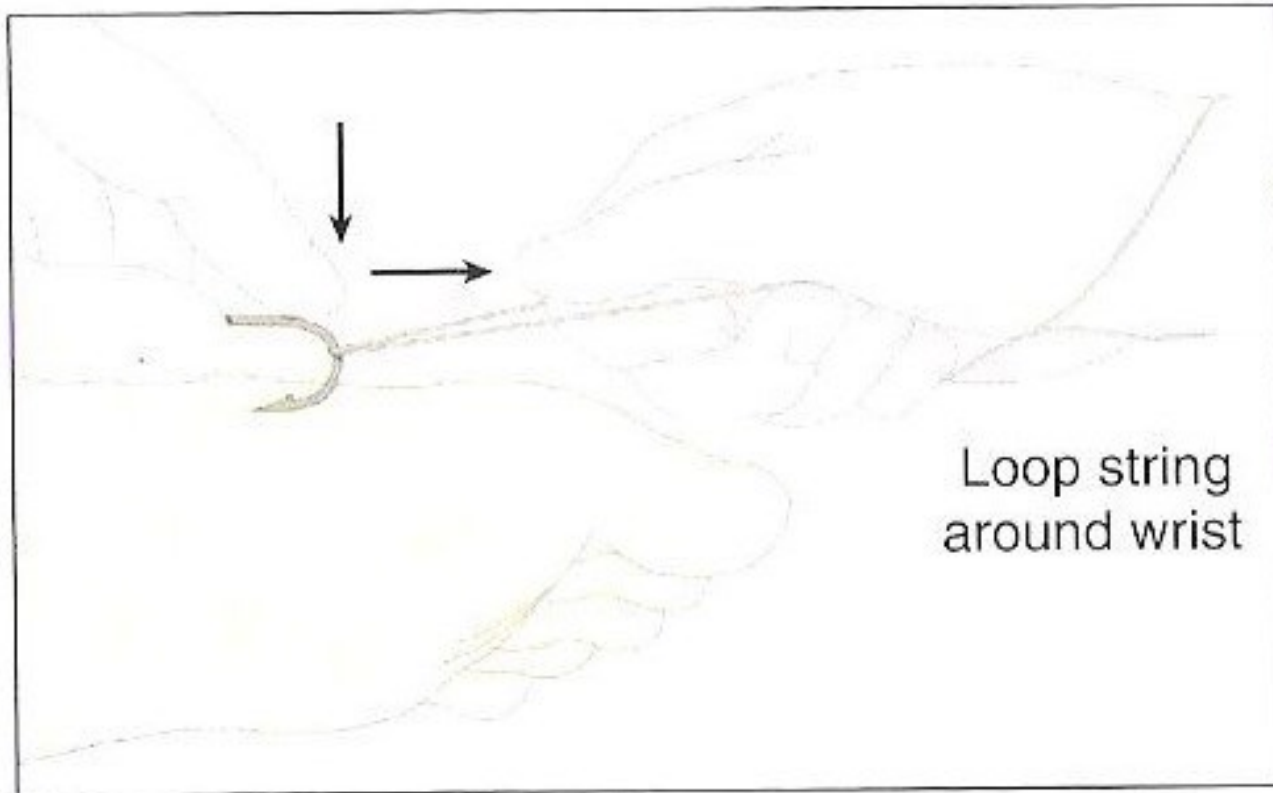
A



B

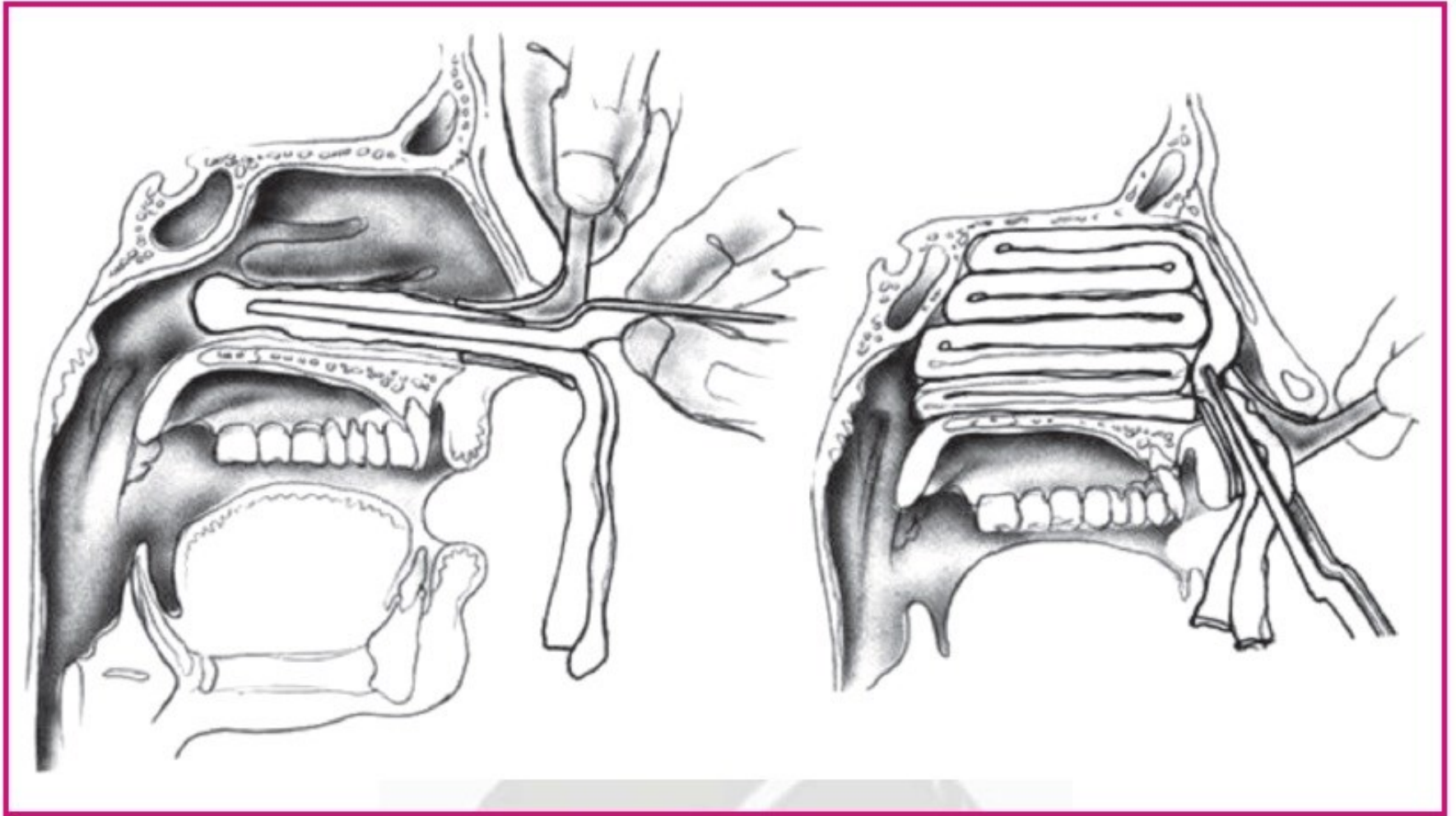


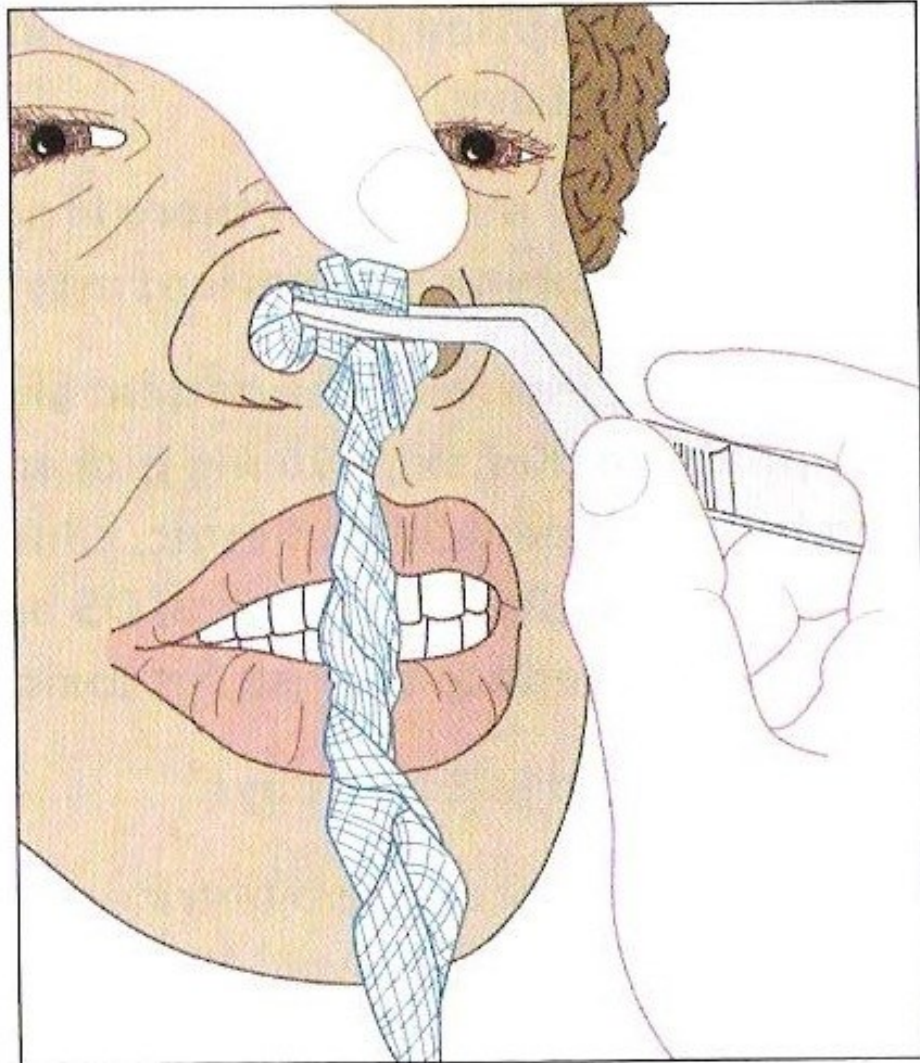
C

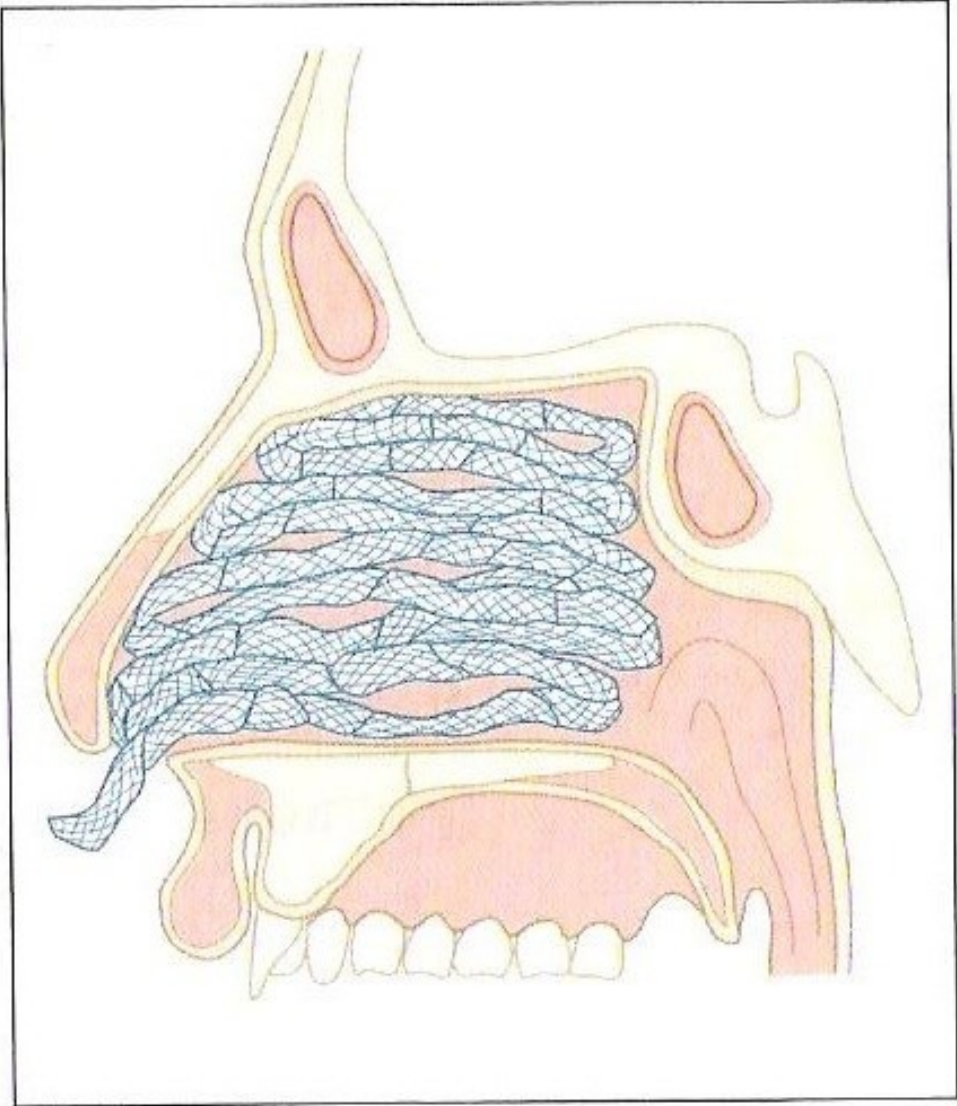


Loop string
around wrist

Tamponamento Nasal Anterior







Lista de Materiais para Procedimentos em APS

- Cuba rim (4 un.)
- Cuba redonda (4 un.)
- Seringa de 20mL ou maior
- Agulhas de vários calibres
- Pinça de Backhaus de 6cm (5 un.)
- Cabo de bisturi nº3
- Lâminas 15 e 11
- Cabo de bisturi cilíndrico tipo Beaver
- Minilâminas Beaver 67 e 65
- Tesoura Metzemaum curva de 14 cm (5 un.)
- Pinça de Adson de 12 cm (5 un.)
- Fio dental
- Pinças hemostáticas de Halsted (mosquito) de 12 cm (6 un. curvas e 4 un. retas)
- Afastadores de Senn (2 un.)
- Ganchos do tipo Gilles-Dingmann
- Porta-agulhas de Derf de 12 cm para fios 5.0 e 6.0 (2 un.)
- Porta-agulhas de Mayo-Hegar de 15 cm para fios 4.0 e mais calibrosos
- Pinça baioneta (2 un.)
- Tenta cânula (6 un.)
- Eletrocautério
- Cadarço

Procedimentos em APS

Vamos Começar?

Obrigado!

umpierre@ufrgs.br